

Towel Clip Reduction of the Depressed Zygomatic Arch Fracture

Todd G. Carter, DMD,* Shabrokh Bagheri, DMD, MD,†
and Eric J. Dierks, DMD, MD‡

Since the first description of a surgical reduction of a zygoma fracture by Duverney in 1751,¹ many varying methods of treatment have been described. Both intraoral and extraoral methods have become commonplace. The transoral approach was popularized by Keen in 1909,² with later modifications by Goldthwaite³ and Quinn.⁴ These techniques offer the advantages of avoiding any skin incision, thereby avoiding any visible scarring. Additionally, they allow for minimal dissection and an excellent vector for reduction; however, they may result in increased rates of infection by introducing oral flora into the infratemporal fossa. Gilles et al⁵ described the temporal fossa approach in 1927, and this became a very popular method for the treatment of isolated arch fractures around the world. Similarly, Dingman and Natvig⁶ described the supraorbital approach as an extraoral alternative in 1964. All of these techniques have in common the use of a Rowe zygoma elevator, urethral sound, Kelly hemostat, or similar instrument placed between the arch and coronoid process to achieve reduction. Others have described several percutaneous methods meant to be less invasive. These include passing wire beneath the arch or using a towel clip to directly grasp the bone fragments and allow for lateral force to be applied. The use of a towel clip passed beneath the arch percutaneously has been described previously in a case series by Hwang and Lee,⁷ but little description of the procedure was offered.

Fractures of the zygoma are common maxillofacial injuries second only to nasal fractures. While many of these are of minimal clinical significance, those that

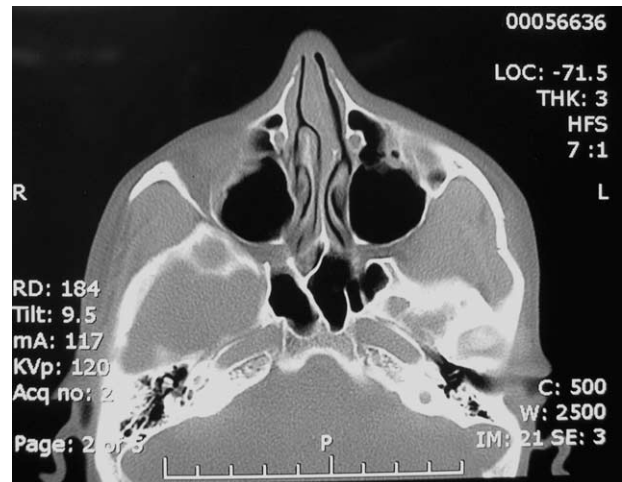

FIGURE 1. Preoperative axial computed tomography scan demonstrates depressed left arch fracture.

Carter, Bagheri, and Dierks. Towel Clip Reduction of Zygomatic Arch. *J Oral Maxillofac Surg* 2005.

possess esthetic deformities or functional limitations demand surgical reduction (Figs 1, 2). Here we describe a simple and effective method for the reduction of the isolated arch fracture that has been used with great success by the senior author (E.J.D.) for over 25 years.

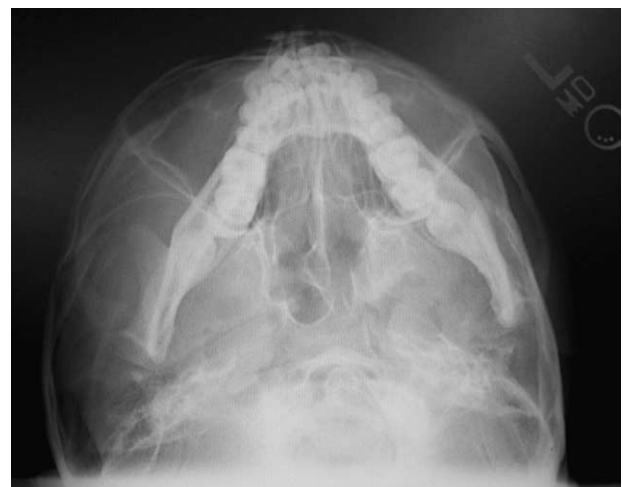

FIGURE 2. Postoperative submentovertex radiograph demonstrates excellent reduction of depressed arch fracture using the towel clip technique.

Carter, Bagheri, and Dierks. Towel Clip Reduction of Zygomatic Arch. *J Oral Maxillofac Surg* 2005.

*Private Practice, Wailuku, HI; Formerly, Chief Resident, Oral and Maxillofacial Surgery, Department of Oral and Maxillofacial Surgery, University of Washington, Seattle, WA.

†Fellow in Craniomaxillofacial Trauma and Cosmetic Surgery, Legacy Emanuel Hospital, Portland, OR.

‡Private Practice, Atlanta, GA, and Clinical Assistant Professor of Oral and Maxillofacial Surgery, Emory University, Atlanta, GA; Formerly, Fellow in Craniomaxillofacial Trauma and Cosmetic Surgery, Legacy Emanuel Hospital, Portland, OR.

Address correspondence and reprint requests to Dr Carter: 1063 Lower Main St, Suite C221, Wailuku, HI 96793.

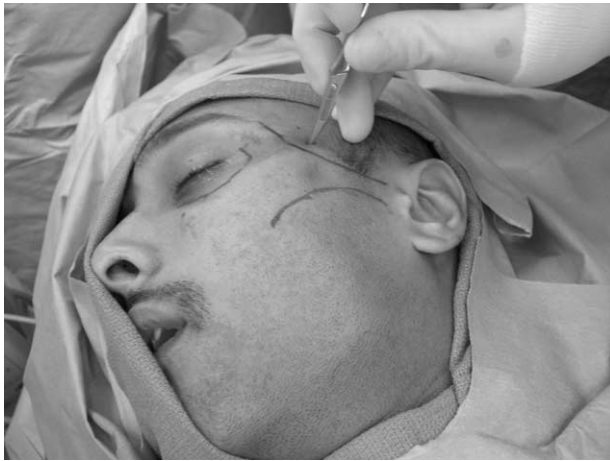

FIGURE 3. Placement of superior stab incision.

Carter, Bagheri, and Dierks. Towel Clip Reduction of Zygomatic Arch. J Oral Maxillofac Surg 2005.

Technique

The involved area is sterilely prepped and draped, leaving the ipsilateral eye, ear, and oral commissure exposed for orientation. The lateral orbital rim, malar prominence, and arch are then outlined with a marking pen. The area of depression is then palpated. The area immediately superior and inferior to the fracture site is infiltrated with a local anesthetic with vasoconstrictor. A No. 11 blade is then used to make a small stab incision through the skin approximately 1 cm superior to the fracture site (Figs 3-6). A large penetrating towel clip (KLS No. 13-915-15; KLS Martin, Jacksonville, FL) (Fig 7) is opened widely, and one tine is introduced and passed deep to the depressed arch (Fig 8). It should be noted that the depth of the fracture is easily underestimated, and care should be taken to ensure that the tine passes between the

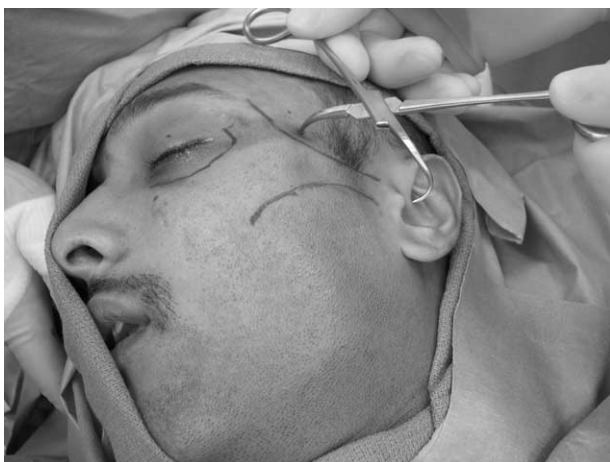

FIGURE 4. Passage of superior tine deep to depressed arch.

Carter, Bagheri, and Dierks. Towel Clip Reduction of Zygomatic Arch. J Oral Maxillofac Surg 2005.

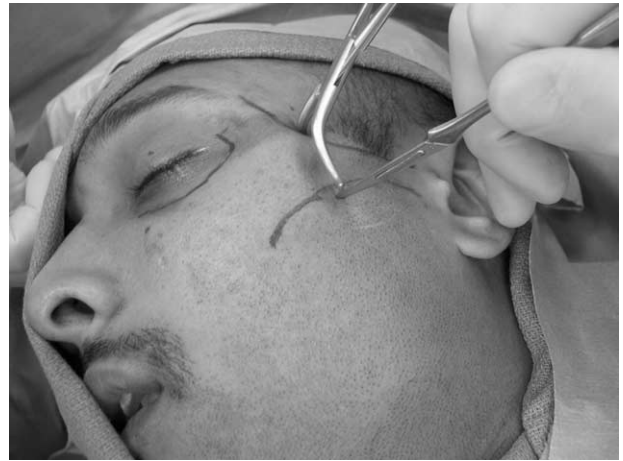

FIGURE 5. Placement of inferior stab incision after rotation of towel clip.

Carter, Bagheri, and Dierks. Towel Clip Reduction of Zygomatic Arch. J Oral Maxillofac Surg 2005.

coronoid process and the medially displaced arch fragment. The towel clip is then partially closed, and the site for the inferior stab incision is identified. A No. 11 blade is used to make the second stab incision. The inferior tine of the towel clip is then passed, and the clip is closed and latched into position. The patient's head is stabilized, and firm but steady lateral force is applied. The fragments can be felt reducing into appropriate position, and a click may or may not be appreciated. Steady force is maintained for several seconds to ensure that the fragments are reduced laterally as much as possible as there may be a tendency for some relapse as the force is diminished. The area is then palpated for symmetry with the contralateral arch, and the esthetics evaluated. The clip is removed when adequate reduction has been ensured.

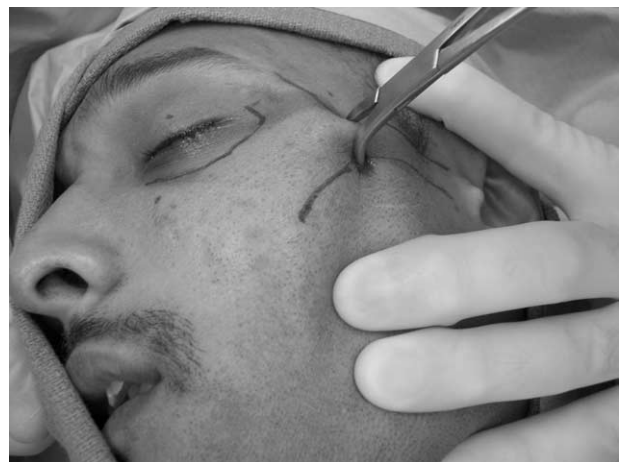

FIGURE 6. Application of lateral reducing force while stabilizing patient's head.

Carter, Bagheri, and Dierks. Towel Clip Reduction of Zygomatic Arch. J Oral Maxillofac Surg 2005.

Each stab incision is closed with a single 6-0 fast absorbing gut suture. The use of a protective dressing such as a finger splint or eye shield is optional.

Discussion

The towel clip method is a quick, simple, and effective technique for the reduction of a depressed zygomatic arch fracture. It is minimally invasive, carries little risk of infection or neurovascular injury, and leaves no visible scarring. This technique may be performed under local anesthesia or sedation in an emergency department or clinic setting, making it a highly cost-effective addition to the oral and maxillofacial surgeon's armamentarium.

Acknowledgment

The authors would like to acknowledge Gerald Harper, DDS; Springfield, OR, for contributing the illustration included in this article.

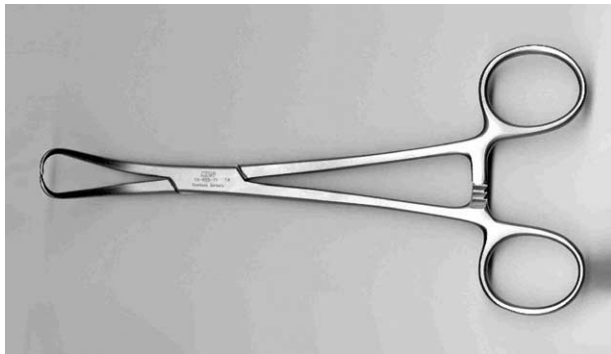


FIGURE 7. Large penetrating towel clip (KLS No. 13-915-15).

Carter, Bagheri, and Dierks. Towel Clip Reduction of Zygomatic Arch. J Oral Maxillofac Surg 2005.

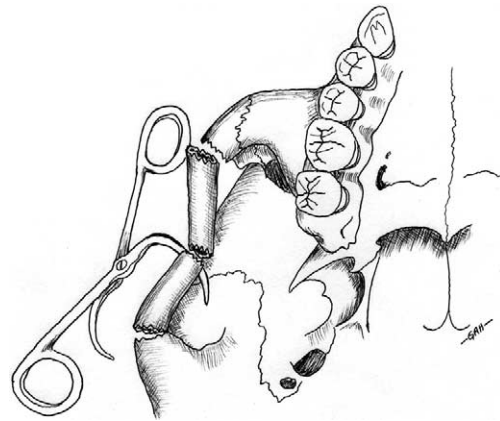


FIGURE 8. Artist's rendering of superior line of towel clip placed deep to the depressed arch prior to rotation and penetration of inferior line (Gerald Harper, DDS; Springfield, OR).

Carter, Bagheri, and Dierks. Towel Clip Reduction of Zygomatic Arch. J Oral Maxillofac Surg 2005.

References

1. Duverney JG: La fracture de l'apophyse zygomatique. *Traite des Maladies des Os* 1:182, 1751
2. Keen WW: *Surgery: Its Principles and Practice*. Philadelphia, PA, Saunders, 1909
3. Goldthwaite RH: Plastic repair of depressed fracture of lower orbital rim. *JAMA* 82:628, 1924
4. Quinn JH: Lateral coronoid approach for intra-oral reduction of fractures of the zygomatic arch. *J Oral Surg* 35:321, 1977
5. Gilles HD, Kilner TP, Stone D: Fractures of the malar-zygoma compound, with a description of a new x-ray position. *Br J Surg* 14:651, 1927
6. Dingman RO, Natvig P: *Surgery of Facial Fractures*. Philadelphia, PA, Saunders, 1964, pp 211-245
7. Hwang K, Lee SI: Reduction of zygomatic arch fracture using a towel clip. *J Craniofac Surg* 10:5, 1999